

Review

# A review of plantar heel pain of neural origin: Differential diagnosis and management

Ali M. Alshami\*, Tina Souvlis, Michel W. Coppieters

*Division of Physiotherapy, School of Health and Rehabilitation Sciences, The University of Queensland, St Lucia, Qld. 4072, Australia*

Received 18 January 2006; received in revised form 28 December 2006; accepted 15 January 2007

## Abstract

Plantar heel pain is a symptom commonly encountered by clinicians. Several conditions such as plantar fasciitis, calcaneal fracture, rupture of the plantar fascia and atrophy of the heel fat pad may lead to plantar heel pain. Injury to the tibial nerve and its branches in the tarsal tunnel and in the foot is also a common cause. Entrapment of these nerves may play a role in both the early phases of plantar heel pain and recalcitrant cases. Although the contribution of nerve entrapment to plantar heel pain has been well documented in the literature, its pathophysiology, diagnosis and management are still controversial. Therefore, the purpose of this article was to critically review the available literature on plantar heel pain of neural origin. Possible sites of nerve entrapment, effectiveness of diagnostic clinical tests and electrodiagnostic tests, differential diagnoses for plantar heel pain, and conservative and surgical treatment will be discussed.

© 2007 Elsevier Ltd. All rights reserved.

*Keywords:* Subcalcaneal pain; Plantar fasciitis; Nerve entrapment; Neurodynamics

## 1. Introduction

Plantar heel pain is a common condition (Hurwitz, 1997; Juliano and Harris, 2004). It occurs in approximately 15% of all adults with foot problems (McCarthy and Gorecki, 1979). Several well-known conditions may lead to plantar heel pain such as plantar fasciitis, calcaneal fracture, rupture of the plantar fascia and atrophy of the heel fat pad (Schon et al., 1993). Plantar heel pain may also have a neural origin, with a lesion or dysfunction of the tibial, plantar or calcaneal nerves (Johnson et al., 1992; Goolsby, 2003). Nerve entrapment may play a role in both acute and chronic conditions of plantar heel pain (Kenzora, 1987; Oztuna et al., 2002).

The first reference to plantar heel pain of neural origin was published in a Dutch language article by Roegholt in 1940. Based on dissection studies, Roegholt postulated that plantar heel pain could be due to entrapment

of the inferior calcaneal nerve (cited in Rondhuis and Huson, 1986). However, nerve entrapment as a cause of plantar heel pain was neglected during the following two decades. In 1960, Kopell and Thompson (1960) hypothesised that trauma to the calcaneal nerves could cause plantar heel pain. To date, although nerve entrapment in plantar heel pain is well documented (e.g. Baxter and Pfeffer, 1992; Oztuna et al., 2002), its pathophysiology, diagnosis and management are still subject to debate.

The aim of this article was to critically review the literature on plantar heel pain of neural origin. We will discuss possible sites of nerve entrapment, the clinical presentation, differential diagnoses, and conservative and surgical treatment.

## 2. Search strategy

Peer-reviewed journal articles that predominantly focused on plantar heel pain of neural origin or that

\*Corresponding author. Tel.: +61 7 3346 7468; fax: +61 7 3365 1622.

E-mail address: [a.alshami@shrs.uq.edu.au](mailto:a.alshami@shrs.uq.edu.au) (A.M. Alshami).

discussed relevant biomechanics of the tibial, plantar and calcaneal nerves were included in this review. Non-English language reports were excluded. Studies were identified using the following databases: Ovid Medline (from 1966 to 07/2006), Web of Science (from 1900 to 07/2006), PubMed (from 1930 to 07/2006), PEDro (07/2006), EMBASE (from 1900 to 07/2006), Cochrane Database of Systematic Reviews (1800 to 07/2006), Cochrane Central Register of Controlled Trials (from 1800 to 07/2006), CINAHL (from 1982 to 07/2006) and AMED (from 1985 to 07/2006). The keywords 'heel pain', 'painful heel', 'plantar fasciitis', 'heel spur' and 'foot pain' were combined with each of the following search terms: 'nerve', 'entrapment', 'compression', 'tibial', 'plantar' and 'calcaneal'. Reference lists of located articles were also searched. This search strategy identified 69 journal articles. Of these, 57 were primary articles (Table 1) while the remaining 12 were review papers (Table 2). Tables are only published in the online version of this article.

### 3. Nerve entrapment sites

The tibial nerve is the larger of the two major divisions of the sciatic nerve, and distally it divides into the following branches: medial calcaneal nerve (MCN), medial plantar nerve (MPN), lateral plantar nerve (LPN) (Gray et al., 2005) and the first branch of the LPN (Przylucki and Jones, 1981) (Fig. 1).

While contribution of the MCN to plantar heel pain of neural origin is well documented (Savastano, 1985; Beito et al., 1989), most authors have implicated the first branch of the LPN in this condition (Baxter and Pfeffer, 1992; Watson et al., 2002). Patients with entrapment of the first branch of the LPN represent 15–20% of the patients with chronic plantar heel pain (Baxter et al., 1989; Pfeffer, 2001). Compression of the tibial nerve at the tarsal tunnel, a condition called tarsal tunnel syndrome (TTS), can also contribute to plantar heel pain (Kinoshita et al., 2001; Lau and Stavrou, 2004). Entrapment of the MPN occurs where the fascial sling can bind the nerve beneath the talus and navicular bone (Schon, 1994; McCluskey and Webb, 1999). We will discuss entrapment of these nerves in detail below.

#### 3.1. Entrapment of the LPN and its first branch

The LPN supplies most of the foot muscles and the skin of the lateral one-third of the plantar aspect of the foot and the fourth and fifth toes (Gray et al., 2005) (Fig. 2). Entrapment of the LPN can result from compression between the abductor hallucis and quadratus plantae muscles (Peri, 1991; May et al., 2002).

The first branch of the LPN, also called the nerve to abductor digiti minimi (Przylucki and Jones, 1981),

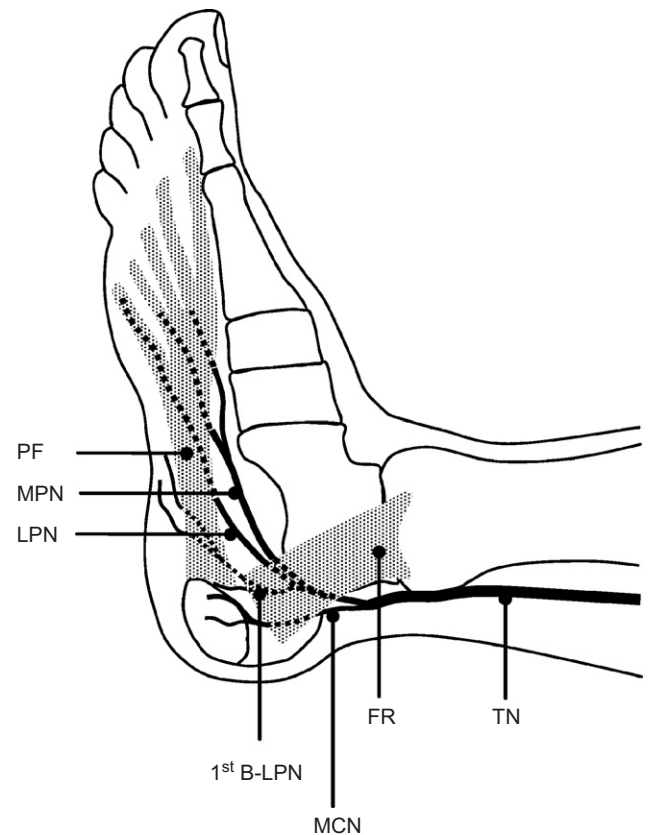


Fig. 1. Medial view of right foot demonstrating the relation of the nerves to other structures. 1st B-LPN, first branch of lateral plantar nerve (LPN); FR, flexor retinaculum; MCN, medial calcaneal nerve; MPN, medial plantar nerve; PF, plantar fascia; TN, tibial nerve.

innervates the flexor digitorum brevis, quadratus plantae and abductor digiti minimi muscles (Przylucki and Jones, 1981; Louisia and Masquelet, 1999). Although it gives off sensory branches to the calcaneal periosteum (Arenson et al., 1980; Rondhuis and Huson, 1986), this nerve does not supply the skin (Park and Del Toro, 1996; Dellon, 2001).

Variations in the origin of the first branch of the LPN have been reported. The branch may either originate rather distally from the LPN (Gray et al., 2005) or relatively proximally (0.5 cm (Arenson et al., 1980) to 1.7 cm (Louisia and Masquelet, 1999) distal to the medial calcaneal tuberosity) (Fig. 3). The close proximity of this nerve to the calcaneal tuberosity suggests the possibility of an entrapment, resulting in plantar heel pain (Przylucki and Jones, 1981; Louisia and Masquelet, 1999).

The majority of studies included in this review reported that entrapment of the first branch of the LPN is the most common cause of plantar heel pain of neural origin (Table 1, electronic version only). Entrapment of this nerve can occur at different sites: (1) where the nerve passes at the sharp edge of the deep fascia of the abductor hallucis and (2) just distal to the medial

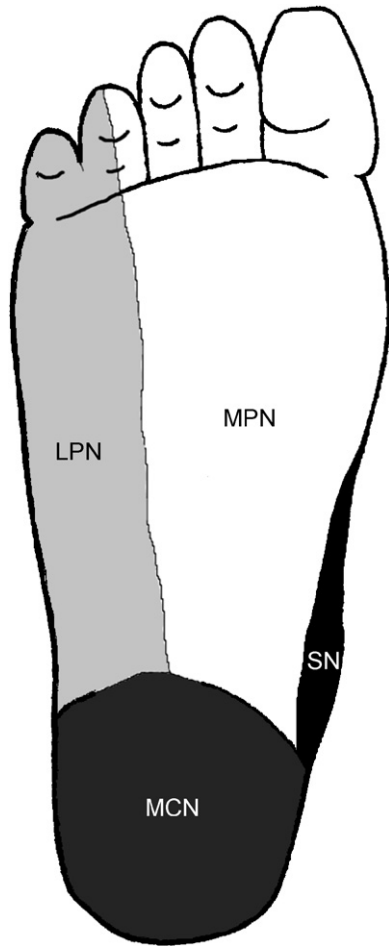


Fig. 2. Cutaneous innervation of the sole of right foot. LPN, lateral plantar nerve; MCN, medial calcaneal nerve; MPN, medial plantar nerve; SN, saphenous nerve.

edge of the calcaneus (Baxter and Thigpen, 1984), particularly in the presence of a calcaneal spur or plantar fasciitis (Przylucki and Jones, 1981; Louisia and Masquelet, 1999). While Rondhuis and Huson (1986) did not observe the first site in either 4 foetal or 34 adult dissected feet, they reported a site of possible entrapment between the abductor hallucis and the medial head of quadratus plantae muscle (Fig. 4). Histological examination of this nerve revealed hypertrophy of the perineural connective tissues (Przylucki and Jones, 1981), loss of large myelinated fibres and an increase in endoneurial collagen, suggesting chronic compression (Baxter and Pfeffer, 1992).

### 3.2. Entrapment of the MCN

The MCN usually divides into anterior and posterior branches (Henricson and Westlin, 1984; Louisia and Masquelet, 1999). It provides sensory innervation to most of the heel fat pad and to the superficial tissues overlying the inferior part of the calcaneus (Louisia and Masquelet, 1999) (Fig. 2).

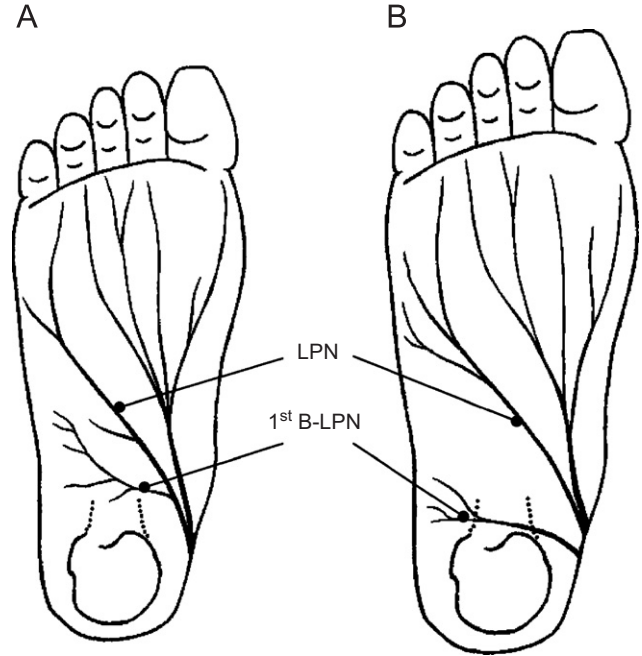


Fig. 3. Variations in the distribution of the first branch of lateral plantar nerve (1st B-LPN). (A) The nerve originates more distally from the LPN as described in Gray's anatomy. (B) The nerve branches off more proximally as shown in cadaver studies. Adapted from Przylucki and Jones (1981) and original reproduced by kind permission of The American Podiatric Medical Association.

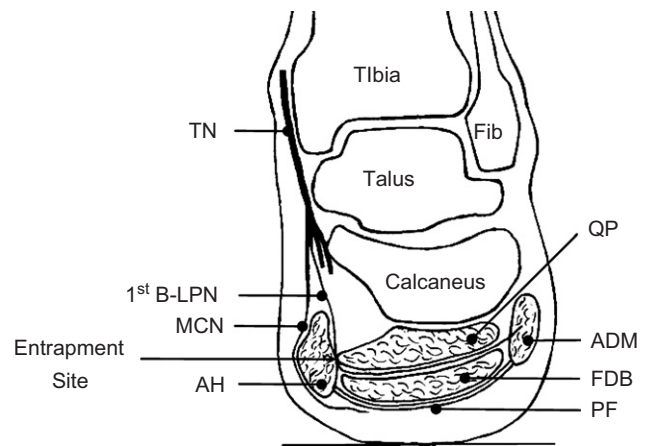


Fig. 4. Cross-sectional view of right ankle and foot. Note the possible entrapment site of the first branch of lateral plantar nerve (1st B-LPN) between the deep fascia of the abductor hallucis (AH) muscle and the medial head of quadratus plantae (QP) muscle. ADM, abductor digiti minimi; Fib, fibula; FDB, flexor digitorum brevis; MCN, medial calcaneal nerve; PF, plantar fascia; TN, tibial nerve. Adapted from Baxter and Pfeffer (1992) and original reproduced by kind permission of Lippincott Williams and Wilkins.

MCN is the second most commonly reported nerve that has been related to plantar heel pain of neural origin (Table 1, electronic version only). In a case report, Shacklock (1995) concluded that plantar heel pain and paraesthesiae in a patient with diabetes resulted from a

neuropathy of the MCN and tibial nerve. However, entrapment of the MCN may not be a very prevalent condition as only 5 out of 200 surgical cases were consistent with MCN entrapment (Schon et al., 1993). Most branches of the MCN lie superficially to the abductor hallucis, flexor digitorum brevis and plantar fascia (Arenson et al., 1980; Louisia and Masquelet, 1999). The nerves are less likely to be compressed within these structures, but can be irritated and traumatised following atrophy of the heel fat pad (Kopell and Thompson, 1960; Davidson and Copoloff, 1990).

### 3.3. Entrapment of the MPN

The MPN innervates the abductor hallucis, flexor hallucis brevis, flexor digitorum brevis and first lumbrical, and the skin of the medial two-thirds of the plantar aspect of the foot (Gray et al., 2005) (Fig. 2). Entrapment of the MPN is not as common as entrapment of the other nerves (Murphy and Baxter, 1985), particularly as an isolated entity (Raikin and Schon, 2000). Out of 21 cases diagnosed with nerve entrapment in the ankle and foot, Murphy and Baxter (1985) concluded that only one case was consistent with MPN entrapment.

## 4. Clinical presentation

The diagnosis of plantar heel pain of neural origin is based on a comprehensive history and physical examination (Baxter and Pfeffer, 1992; Jolly et al., 2005).

### 4.1. Pain

In patients with plantar heel pain of neural origin, pain is usually characterised as burning, sharp, shooting, shock-like, electric, localised or radiating either proximally or distally (Schon et al., 1993; Goecker and Banks, 2000), and occasionally as dull aching (Fredericson et al., 2001; May et al., 2002). Typically, pain is worse during or after weight-bearing activities and improves with rest (Pfeffer, 1995; May et al., 2002). However, pain may also occur with rest and in non-weight bearing positions (Hendrix et al., 1998; Barrett and O'Malley, 1999). Pain at night may be due to nerve compression as a result of venostasis (slowing of venous outflow) and venous engorgement (local congestion and distension with blood) (Kopell and Thompson, 1960; Doxey, 1987).

### 4.2. Post-static dyskinesia

A common finding in patients with plantar heel pain of neural origin is pain when a patient first stands after periods of rest, a phenomenon called post-static

dyskinesia (Oztuna et al., 2002; Jolly et al., 2005). Severe pain in the morning after rising from bed was found in a large number of patients with plantar heel pain of neural origin (Schon et al., 1993; Oztuna et al., 2002).

Post-static dyskinesia is thought to be caused by fluid accumulation around the nerve during rest (Davidson and Copoloff, 1990). Upon taking the first steps, this fluid presses against the nerve, causing pain, and “as the fluid is milked out of the nerve sheath some of the pain subsides”. The fluid then builds up as the day progresses and symptoms may return (Davidson and Copoloff, 1990). Jolly et al. (2005) hypothesised that muscular activity associated with ambulation reduces venous pooling and intra-compartmental pressures. Therefore, pain of neural origin may decrease with sustained ambulation, whereas pain in plantar fasciitis is likely to increase (Jolly et al., 2005). It should be noted, however, that post-static dyskinesia is not pathognomonic for plantar heel pain of neural origin. It also occurs frequently in patients with plantar fasciitis.

### 4.3. Paraesthesiae and neurological changes

Although sensory deficit is not common in entrapment of the first branch of the LPN (Pfeffer and Baxter, 1991), patients with TTS often complain of sensory disturbances (Schon and Baxter, 1990; Schepsis et al., 1991), such as tingling and/or numbness around the medial and plantar aspects of the heel (Baxter, 1994; May et al., 2002). Kinoshita et al. (2001) found that 35 out of 44 feet with TTS had diminished sensation in the distribution of the MPN, 7 had diminished sensation in the distribution of both MPN and LPN, and 2 had diminished sensation in the distribution of both MPN and MCN.

## 5. Diagnostic tests

### 5.1. Clinical tests

#### 5.1.1. Palpation

Palpation over the abductor hallucis and/or on the medial calcaneal tuberosity reproduced symptoms in all patients (33) with suspected neurological plantar heel pain (Schon et al., 1993). The diagnosis of entrapment of the first branch of the LPN should not be made without the presence of maximal tenderness over the nerve, although the entire heel and the proximal plantar fascia may also be tender (Baxter and Pfeffer, 1992; Goecker and Banks, 2000) (Fig. 5). Diagnosis of entrapment of the anterior branch of the MCN can be substantiated by the following palpatory findings: (1) maximal tenderness over the medial anterior part of the heel fat pad and abductor hallucis, (2) distally radiating pain with



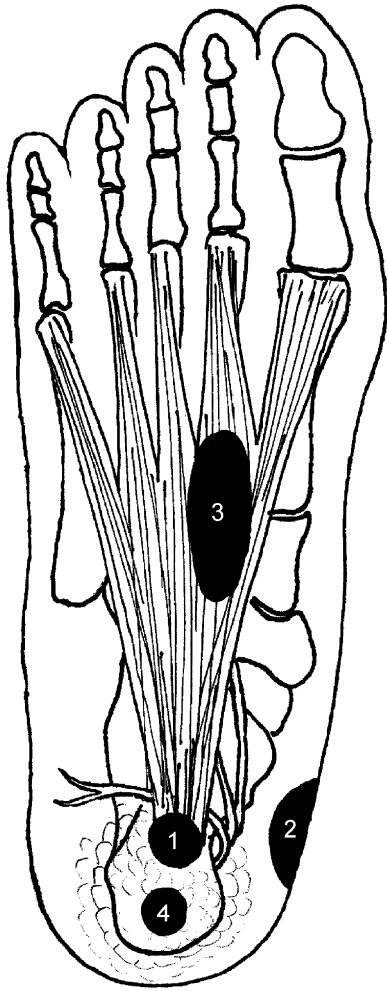


Fig. 5. Sole of right foot with areas of maximal tenderness for different conditions associated with plantar heel pain: (1) plantar fasciitis (or heel pain syndrome according to [Spiegel and Johnson \(1984\)](#); [Kenzora \(1987\)](#) and [Pfeffer and Baxter \(1991\)](#)), (2) entrapment of the first branch of lateral plantar nerve, (3) true/isolated plantar fasciitis according to [Pfeffer and Baxter \(1991\)](#) and [Karr \(1994\)](#) and (4) fat pad atrophy. Adapted from [Baxter and Pfeffer \(1992\)](#) and original reproduced by kind permission of Lippincott Williams and Wilkins.

pressure on the nerve and (3) only minimal tenderness over the plantar fascia origin ([Henricson and Westlin, 1984](#)). With MPN entrapment, tenderness is typically located over the plantar aspect of the medial arch around the navicular tuberosity ([Schon and Baxter, 1990](#)).

#### 5.1.2. Dorsiflexion-eversion and neurodynamic tests

[Kinoshita et al. \(2001\)](#) devised the dorsiflexion-eversion (DF/Eve) test for TTS. With this test, all metatarsophalangeal joints are passively extended while the ankle is held in dorsiflexion and eversion. This test reproduced or aggravated the symptoms in the majority of patients with TTS (36 out of 44 feet), but not in a healthy control group ([Kinoshita et al., 2001](#)).

Cadaver studies showed a significant increase in tension in the tibial nerve and LPN within the tarsal tunnel during dorsiflexion, eversion and combined DF/Eve ([Daniels et al., 1998](#); [Lau and Daniels, 1998](#)). Metatarsophalangeal extension further increases strain in the MPN and tibial nerve ([Alshami et al., 2007](#)). Unfortunately, metatarsophalangeal extension also increases strain in the plantar fascia ([Alshami et al., 2007](#)), which may compromise the usefulness of the DF/Eve test in the differential diagnosis of plantar heel pain.

In order to differentiate between structures, neurodynamic tests have been suggested for plantar heel pain ([Butler, 2000, p. 414](#); [Shacklock, 2005, pp. 232–235](#)). These tests are sequences of movements aimed to “test the mechanics and physiology of a part of the nervous system” ([Butler, 2000, p. 98](#)). In a case study, [Meyer et al. \(2002\)](#) could reproduce plantar heel pain of neural origin with hip flexion when added to DF/Eve (a modified straight leg-raising test). In a biomechanical study, [Coppeters et al. \(2006\)](#) demonstrated that adding hip flexion to ankle dorsiflexion with the knee in extension increased strain in the tibial and plantar nerves at the ankle and foot, without increasing tension in the plantar fascia. Although clinical studies are needed, this suggests that the modified straight leg-raising test may be a valuable tool to differentiate plantar heel pain of neural origin from other common conditions, such as plantar fasciitis.

#### 5.1.3. Plantar flexion-inversion test

Passive plantar flexion-inversion may reproduce or aggravate symptoms as the test increases pressure on the tibial nerve in the tarsal tunnel ([Trepman et al., 1999](#)). During surgery, [Hendrix et al. \(1998\)](#) observed that this manoeuvre reduced the width of the tarsal canal and compressed the LPN, and the first branch of the LPN and MPN.

#### 5.1.4. Tinel’s test

Tinel’s test consists of tapping along the course of a nerve. The test is considered positive when it results in tingling along the nerve distribution. While Tinel’s test is often positive in TTS ([Schon and Baxter, 1990](#); [Kinoshita et al., 2001](#)), and can be positive in MPN entrapment ([Schon and Baxter, 1990](#)), the test is usually negative in entrapment of the first branch of the LPN ([Fredericson et al., 2001](#)). [Baxter and Pfeffer \(1992\)](#) found a positive Tinel’s test in only 12 of 69 heels (17%) with entrapment of the first branch of the LPN.

## 5.2. Electrodiagnostic tests

#### 5.2.1. Electromyography and nerve conduction studies

Electromyography and nerve conduction studies have revealed abnormalities in the MPN ([Schon et al., 1993](#)) and LPN ([Johnson et al., 1992](#); [Schon et al., 1993](#)).

However, their role in the diagnosis of nerve involvement in plantar heel pain is controversial. Schon et al. (1993) reported that electrodiagnostic tests are only an adjunct and are not a substitute for clinical examination. In general, up to 50% of electrophysiological studies can return false-negative results for large nerve compression neuropathies (Dellon, 1999) and they are even less accurate for smaller nerve fibres (Magda et al., 2002).

### 5.2.2. Quantitative sensory testing

Quantitative sensory testing (QST) aims to determine pain mechanisms by assessing the function of both large and small sensory nerve fibres (Magda et al., 2002; Siao and Cros, 2003). QST devices generate vibratory, thermal and painful stimuli as well as electrical impulses (Shy et al., 2003). Although it should not be the only tool to diagnose neurological disorders, Shy et al. (2003) concluded that QST is potentially a useful method to measure sensory impairment.

Only a few studies have used some modalities of QST to investigate sensory dysfunctions in patients with plantar heel pain (Tassler and Dellon, 1996; Rose et al., 2003). Tassler and Dellon (1996) demonstrated higher cutaneous pressure thresholds in 22 patients with TTS compared to age-matched controls. Rose et al. (2003) found higher pressure thresholds in the cutaneous distribution of the MCN in 59 of 82 patients (72.2%) with plantar heel pain compared with normative, age-related pressure thresholds. Because they found abnormalities in the cutaneous distribution of both the MCN and MPN in 49.5% of the patients, Rose et al. (2003) concluded that a more proximal disorder, such as lumbosacral nerve root compression, should also be considered.

### 5.3. High-resolution ultrasound

Ultrasound imaging can be used to detect nerve pathology. However, the majority of studies have focused on the median nerve at the carpal tunnel. Nerve swelling (Wong et al., 2002; Yesildag et al., 2004) and diminished lateral movement of the median nerve (Greening et al., 2001) have been demonstrated. Although ultrasound has been suggested for differential diagnosis of TTS (Peer et al., 2003), studies are not yet available.

## 6. Differential diagnoses

Hendrix et al. (1998) found that all of their 51 patients with chronic plantar heel pain due to nerve entrapment demonstrated (1) loss of plantar sensation, (2) a positive plantar flexion-inversion test, (3) a positive Tinel's test and (4) pain and paraesthesia on nerve compression. Jolly et al. (2005) suggested that the presence of all of

the above-mentioned signs strongly support a neurogenic cause of plantar heel pain, whereas the presence of only one sign should not be considered until other causes such as plantar fasciitis have been excluded. Although further validation is required, we believe that QST and neurodynamic tests such as the modified straight leg-raising test may also have a role in the diagnosis of plantar heel pain of neural origin. Among others, the following differential diagnoses should be ruled out.

### 6.1. Plantar fasciitis

Plantar fasciitis is the most common cause of plantar heel pain (Aldridge, 2004) and the term has been used generically to describe heel pain at the origin of the plantar fascia on the medial calcaneal tuberosity (Lemont et al., 2003). Chronic plantar fasciitis is predominantly characterised by a marked collagen degeneration of the plantar fascia and inflammation has been rarely reported (Wearing et al., 2006). The typical presentation is pain that is worse when standing after periods of rest or on taking the first steps in the morning (post-static dyskinesia) (Aldridge, 2004). Maximal tenderness is located over the origin of the plantar fascia and along the fascia 1–2 cm distal to the origin (Henricson and Westlin, 1984; Pfeffer and Baxter, 1991) (Fig. 5).

As it is difficult to differentiate between pain from the origin of the plantar fascia and bony sources of heel pain at the medial calcaneal tuberosity, such as calcaneal periostitis, some authors advocate the term 'heel pain syndrome' to refer to pain over the medial calcaneal tuberosity (Spiegel and Johnson, 1984; Kenzora, 1987; Pfeffer and Baxter, 1991). Pfeffer and Baxter (1991) and Karr (1994) reserve the term 'true/isolated plantar fasciitis' to a disorder that affects the middle portion of the plantar fascia.

### 6.2. Fat pad atrophy

In patients with a soft and thin heel fat pad, pain is usually aggravated by hard-soled shoes and walking on hard surfaces. Pain is most intense over the central portion of the heel fat pad (Fig. 5). The pain does not radiate, and the medial calcaneal tuberosity and plantar fascia are not tender (Pfeffer and Baxter, 1991; Baxter and Pfeffer, 1992).

### 6.3. Tumours

Although uncommon, benign tumours or neuromas of the first branch of the LPN (Shandles et al., 2002; Marui et al., 2004), MCN (Davidson, 1977) and MPN (Marui et al., 2004) have been related to plantar heel pain. Patients with neuroma of the MCN may complain

of occasional local paraesthesia and loss of sensation (Davidson et al., 1977), and a Tinel's test may also be positive (Davidson and Copoloff, 1990).

#### 6.4. Proximal nerve lesions

Neurological examination should be performed to exclude proximal nerve disorders (Jolly et al., 2005). Schon et al. (1993) found that 2 patients out of 23 with plantar heel pain had electrophysiological evidence of S1 radiculopathy. The tibial nerve in the popliteal fossa can be compressed by the tendinous arch of the soleus muscle (Mastaglia, 2000) or by a Baker's cyst (Willis and Carter, 1998), which can radiate pain to the heel.

Other differential diagnoses such as rupture of the plantar fascia, bone fractures, bursitis, tendonitis, arthritis, osteomyelitis and bone cysts (Brown, 1996; Aldridge, 2004) should also be considered.

### 7. Treatment

Surprisingly, according to the literature, the current treatment of plantar heel pain due to nerve entrapment is similar to other types of plantar heel pain (Baxter et al., 1989; Johnston, 1994). The fact that the conservative management of plantar heel pain is still challenging (Watson et al., 2002) can be attributed to the difficulties in establishing the correct differential diagnosis and aetiology.

#### 7.1. Conservative treatment

In general, conservative treatment of plantar heel pain may include rest, non-steroidal anti-inflammatory drugs, corticosteroid injections, extracorporeal shock wave therapy, laser, local anaesthetic injections, heel pads and heel cups, night splints, medial longitudinal arch supports, strapping, foot orthoses, soft-soled shoes, stretching exercises for the Achilles tendon and plantar fascia, ultrasound and casting (e.g. Pfeffer, 1995; Crawford and Thomson, 2003). In a systematic review, Crawford and Thomson (2003) concluded that the effectiveness of the treatment modalities for plantar heel pain have not been established in randomised controlled trials. They found limited evidence for the effectiveness of local corticosteroid therapy for short-term pain relief, usually around 4 weeks. However, complications such as plantar fascia rupture can result from corticosteroid injections (Sellman, 1994; Acevedo and Beskin, 1998).

There is a limited number of case studies that have applied nerve mobilisation techniques in the treatment of patients with plantar heel pain of neural origin (Shacklock, 1995; Meyer et al., 2002). Shacklock (1995) used knee extension movements in supine position in a

patient with a neuropathy of the MCN and tibial nerve at the tarsal tunnel. Meyer et al. (2002) performed knee extension movements in a slump position in a patient with a possible entrapment of the MCN and tibial nerve at the ankle and/or at the arch of the soleus muscle. Both case studies reported positive outcomes with no adverse effects.

#### 7.2. Surgical interventions

Approximately half of the identified primary articles were surgical studies (Table 1, electronic version only). Surgery is considered if at least 6–12 months of conservative treatment has failed (Karr, 1994; Watson et al., 2002). Surgical decompression of the first branch of the LPN (Baxter and Pfeffer, 1992; Sammarco and Helfrey, 1996; Conflitti and Tarquinio, 2004), MCN (Davidson, 1977; Bordelon, 1983; Savastano, 1985), LPN and MPN (Hendrix et al., 1998) relieved symptoms in patients with plantar heel pain.

Bordelon (1983) and Watson et al. (2002) suggested that a combination of surgical procedures may be needed only if a specific diagnosis cannot be made. Nevertheless, for the majority of the reviewed primary studies it is difficult to establish the effect of a specific surgical intervention as often several surgical procedures were performed simultaneously and control interventions were not considered.

Postoperatively, different protocols have been briefly discussed in the literature. Generally, the use of special postoperative shoes or walking casts has been recommended for a period of 1–4 weeks. After cast removal, weight bearing is resumed as tolerated and active range of motion exercises are encouraged (Beito et al., 1989; Hendrix et al., 1998; Watson et al., 2002).

### 8. Conclusion and recommendations

Through the decades, attention has shifted away from considering inflammation of the plantar fascia as the principal source of plantar heel pain. Recently, nerve entrapment has also been considered an important cause of plantar heel pain. In particular, the first branch of the LPN and the MCN are implicated in this condition. The diagnosis of plantar heel pain with a neural origin is dependent on a careful history and physical examination. Evidence for the role of QST in the diagnosis is emerging. The authors believe that the current inconsistency in the literature regarding the diagnosis and management of plantar heel pain with a neural origin can be explained by (1) difficulty in establishing the correct cause of plantar heel pain, (2) lack of prospective-controlled studies, (3) different characteristics of subjects and different methodologies used in the studies, (4) complexity of foot anatomy and biomechanics and

(5) complexity of neuropathic pain in terms of its pathophysiology, diagnosis and treatment. Based on the available literature, there is lack of evidence on treatment approaches although the majority of patients with plantar heel pain improve with conservative treatment. Further studies are needed to investigate the mechanisms of pain in patients with plantar heel pain and to establish the role of QST and neurodynamic tests such as modified straight leg-raising in differential diagnosis of neurological plantar heel pain. Studies that investigate the benefits of adding specific nerve gliding exercises to the conservative and postoperative management of plantar heel pain of neural origin are also required.

### Acknowledgements

The authors would like to thank Professor Tom McPoil for his valuable comments on a previous version of this paper.

### Appendix A. Supporting Information

Supplementary data associated with this article can be found in the online version at [doi:10.1016/j.math.2007.01.014](https://doi.org/10.1016/j.math.2007.01.014).

### References

- Acevedo JI, Beskin JL. Complications of plantar fascia rupture associated with corticosteroid injection. *Foot and Ankle International* 1998;19(2):91–7.
- Aldridge T. Diagnosing heel pain in adults. *American Family Physician* 2004;70(2):332–8.
- Alshami A, Babri A, Souvlis T, Coppieters MW. Biomechanical evaluation of two clinical tests for plantar heel pain: the dorsiflexion-eversion test for tarsal tunnel syndrome and the Windlass test for plantar fasciitis. *Foot and Ankle International* 2007;28(4). doi:10.3113/FAI.2007.0000.
- Arenson DJ, Cosentino GL, Suran SM. The inferior calcaneal nerve: an anatomical study. *Journal of the American Podiatry Association* 1980;70(11):552–60.
- Barrett SJ, O'Malley R. Plantar fasciitis and other causes of heel pain. *American Family Physician* 1999;59(8):2200–6.
- Baxter DE. Compressive neuropathies of the foot and ankle. *Operative Techniques in Sports Medicine* 1994;2(1):18–23.
- Baxter DE, Pfeffer GB. Treatment of chronic heel pain by surgical release of the first branch of the lateral plantar nerve. *Clinical Orthopaedics and Related Research* 1992(279):229–36.
- Baxter DE, Pfeffer GB, Thigpen M. Chronic heel pain: treatment rationale. *Orthopedic Clinics of North America* 1989;20(4):563–9.
- Baxter DE, Thigpen CM. Heel pain—operative results. *Foot and Ankle* 1984;5(1):16–25.
- Beito SB, Krych SM, Harkless LB. Recalcitrant heel pain: traumatic fibrosis vs. heel neuroma. *Journal of the American Podiatric Medical Association* 1989;79(7):336–9.
- Bordelon RL. Subcalcaneal pain: a method of evaluation and plan for treatment. *Clinical Orthopaedics and Related Research* 1983(177):49–53.
- Brown C. A review of subcalcaneal heel pain and plantar fasciitis. *Australian Family Physician* 1996;25(6):875–81, 884–5.
- Butler DS. The sensitive nervous system. Unley: Noigroup Publications; 2000. pp. 398–423 [Chapter 15].
- Conflitti JM, Tarquinio TA. Operative outcome of partial plantar fasciectomy and neurolysis to the nerve of the abductor digiti minimi muscle for recalcitrant plantar fasciitis. *Foot and Ankle International* 2004;25(7):482–7.
- Coppieters MW, Alshami AM, Babri AS, Souvlis T, Kippers V, Hodges PW. Strain and excursion of the sciatic, tibial, and plantar nerves during a modified straight leg raising test. *Journal of Orthopaedic Research* 2006;24(9):1883–9.
- Crawford F, Thomson C. Interventions for treating plantar heel pain. *Cochrane Database of Systematic Reviews (Online)* 2003(3):CD000416.
- Daniels TR, Lau JT, Hearn TC. The effects of foot position and load on tibial nerve tension. *Foot and Ankle International* 1998;19(2):73–8.
- Davidson MR. Heel neuroma: identification and removal. *Journal of the American Podiatry Association* 1977;67(6):431–5.
- Davidson MR, Copoloff JA. Neuromas of the heel. *Clinics in Podiatric Medicine and Surgery* 1990;7(2):271–88.
- Davidson MR, Liston H, Jacoby RP, Cohen SJ, Beldon LM, Seidner AN, et al. Heel neuroma. *Journal of the American Podiatry Association* 1977;67(8):589–94.
- Dellon AL. Deciding when heel pain is of neural origin. *The Journal of Foot and Ankle Surgery* 2001;40(5):341–5.
- Dellon AL. Management of peripheral nerve problems in the upper and lower extremity using quantitative sensory testing. *Hand Clinics* 1999;15(4):697–715.
- Doxey GE. Calcaneal pain: a review of various disorders. *Journal of Orthopaedic and Sports Physical Therapy* 1987;9(1):25–32.
- Fredericson M, Standage S, Chou L, Matheson G. Lateral plantar nerve entrapment in a competitive gymnast. *Clinical Journal of Sport Medicine* 2001;11(2):111–4.
- Goecker RM, Banks AS. Analysis of release of the first branch of the lateral plantar nerve. *Journal of the American Podiatric Medical Association* 2000;90(6):281–6.
- Goolsby MJ. Diagnosis and treatment of heel pain. *Journal of the American Academy of Nurse Practitioners* 2003;15(11):485–6.
- Gray H, Standring SM, Ellis H, Berkovitz BKB. Gray's anatomy: the anatomical basis of clinical practice, 39th ed. Edinburgh: Elsevier Churchill Livingstone; 2005.
- Greening J, Lynn B, Leary R, Warren L, O'Higgins P, Hall-Craggs M. The use of ultrasound imaging to demonstrate reduced movement of the median nerve during wrist flexion in patients with non-specific arm pain. *Journal of Hand Surgery—British and European Volume* 2001;26(5):401–6.
- Hendrix CL, Jolly GP, Garbalosa JC, Blume P, DosRemedios E. Entrapment neuropathy: the etiology of intractable chronic heel pain syndrome. *The Journal of Foot and Ankle Surgery* 1998;37(4):273–9.
- Henricson AS, Westlin NE. Chronic calcaneal pain in athletes: entrapment of the calcaneal nerve? *The American Journal of Sports Medicine* 1984;12(2):152–4.
- Hurwitz SH. Plantar heel pain in the adult. *Hosp Pract (Off Ed)* 1997;32(9):81–3 86–8, 91–2.
- Johnson ER, Kirby K, Lieberman JS. Lateral plantar nerve entrapment: foot pain in a power lifter. *The American Journal of Sports Medicine* 1992;20(5):619–20.
- Johnston MR. Nerve entrapment causing heel pain. *Clinics in Podiatric Medicine and Surgery* 1994;11(4):617–24.
- Jolly GP, Zgonis T, Hendrix CL. Neurogenic heel pain. *Clinics in Podiatric Medicine and Surgery* 2005;22(1):101–13.



- Juliano PJ, Harris TG. Plantar fasciitis, entrapment neuropathies, and tarsal tunnel syndrome: current up to date treatment. *Current Opinion in Orthopaedics* 2004;15(2):49–54.
- Karr SD. Subcalcaneal heel pain. *The Orthopedic Clinics of North America* 1994;25(1):161–75.
- Kenzora JE. The painful heel syndrome: an entrapment neuropathy. *Bulletin of the Hospital for Joint Diseases Orthopaedic Institute* 1987;47(2):178–89.
- Kinoshita M, Okuda R, Morikawa J, Jotoku T, Abe M. The dorsiflexion-eversion test for diagnosis of tarsal tunnel syndrome. *The Journal of Bone and Joint Surgery—American Volume* 2001;83-A(12):1835–9.
- Kopell HP, Thompson WA. Peripheral entrapment neuropathies of the lower extremity. *The New England Journal of Medicine* 1960;14(262):56–60.
- Lau JT, Daniels TR. Effects of tarsal tunnel release and stabilization procedures on tibial nerve tension in a surgically created pes planus foot. *Foot and Ankle International* 1998;19(11):770–7.
- Lau JT, Stavrou P. Posterior tibial nerve—primary. *Foot and Ankle Clinics* 2004;9(2):271–85.
- Lemont H, Ammirati KM, Usen N. Plantar fasciitis: a degenerative process (fasciosis) without inflammation. *Journal of the American Podiatric Medical Association* 2003;93(3):234–7.
- Louisia S, Masquelet AC. The medial and inferior calcaneal nerves: an anatomic study. *Surgical and Radiologic Anatomy* 1999;21(3):169–73.
- Magda P, Latov N, Renard MV, Sander HW. Quantitative sensory testing: high sensitivity in small fiber neuropathy with normal NCS/EMG. *Journal of the Peripheral Nervous System* 2002;7(4):225–8.
- Marui T, Yamamoto T, Akisue T, Hitora T, Kawamoto T, Nagira K, et al. Neurilemmoma in the foot as a cause of heel pain: a report of two cases. *Foot and Ankle International* 2004;25(2):107–11.
- Mastaglia FL. Tibial nerve entrapment in the popliteal fossa. *Muscle and Nerve* 2000;23(12):1883–6.
- May TJ, Judy TA, Conti M, Cowan JE. Current treatment of plantar fasciitis. *Current Sports Medicine Reports* 2002;1(5):278–84.
- McCarthy DJ, Gorecki GE. The anatomical basis of inferior calcaneal lesions: a cryomicrotomy study. *Journal of the American Podiatry Association* 1979;69(9):527–36.
- McCluskey LF, Webb LB. Compression and entrapment neuropathies of the lower extremity. *Clinics in Podiatric Medicine and Surgery* 1999;16(1):97–125 vii.
- Meyer J, Kulig K, Landel R. Differential diagnosis and treatment of subcalcaneal heel pain: a case report. *Journal of Orthopaedic and Sports Physical Therapy* 2002;32(3):114–22 [discussion 122–4].
- Murphy PC, Baxter DE. Nerve entrapment of the foot and ankle in runners. *Clinics in Sports Medicine* 1985;4(4):753–63.
- Oztuna V, Ozge A, Eskandari MM, Colak M, Golpinar A, Kuyurtar F. Nerve entrapment in painful heel syndrome. *Foot and Ankle International* 2002;23(3):208–11.
- Park TA, Del Toro DR. Isolated inferior calcaneal neuropathy. *Muscle and Nerve* 1996;19(1):106–8.
- Peer S, Kiechl G, Bonder G. Nerve compression syndromes. In: Peer S, Bodner G, editors. *High-resolution sonography of the peripheral nervous system*. Berlin: Springer; 2003. p. 37–59.
- Peri G. The “critical zones” of entrapment of the nerves of the lower limb. *Surgical and Radiologic Anatomy* 1991;13(2):139–43.
- Pfeffer GB. Plantar heel pain. In: Baxter D E, editor. *The Foot and Ankle in Sport*. St. Louis: Mosby; 1995. p. 195–206.
- Pfeffer GB. Plantar heel pain. *Instructional Course Lectures* 2001;50:521–31.
- Pfeffer GB, Baxter DE. Surgery of the adult heel. In: Jahss M H, editor. *Disorders of the foot and ankle: medical and surgical management*. 2nd ed. Philadelphia: Saunders; 1991. p. 1396–416.
- Przylucki H, Jones CL. Entrapment neuropathy of muscle branch of lateral plantar nerve: a cause of heel pain. *Journal of the American Podiatry Association* 1981;71(3):119–24.
- Raikin SM, Schon LC. Nerve entrapment in the foot and ankle of an athlete. *Sports Medicine and Arthroscopy Review* 2000;8(4):387–94.
- Rondhuis JJ, Huson A. The first branch of the lateral plantar nerve and heel pain. *Acta Morphologica Neerlandico-Scandinavica* 1986;24(4):269–79.
- Rose JD, Malay DS, Sorrento DL. Neurosensory testing of the medial calcaneal and medial plantar nerves in patients with plantar heel pain. *The Journal of Foot and Ankle Surgery* 2003;42(4):173–7.
- Sammarco GJ, Helfrey RB. Surgical treatment of recalcitrant plantar fasciitis. *Foot and Ankle International* 1996;17(9):520–6.
- Savastano AA. Surgical neurectomy for the treatment of resistant painful heel. *Rhode Island Medical Journal* 1985;68(8):371–2.
- Schepesis AA, Leach RE, Gorzyca J. Plantar fasciitis: etiology, treatment, surgical results, and review of the literature. *Clinical Orthopaedics and Related Research* 1991(266):185–96.
- Schon LC. Nerve entrapment, neuropathy, and nerve dysfunction in athletes. *The Orthopedic Clinics of North America* 1994;25(1):47–59.
- Schon LC, Baxter DE. Neuropathies of the foot and ankle in athletes. *Clinics in Sports Medicine* 1990;9(2):489–509.
- Schon LC, Glennon TP, Baxter DE. Heel pain syndrome: electrodiagnostic support for nerve entrapment. *Foot and Ankle* 1993;14(3):129–35.
- Sellman JR. Plantar fascia rupture associated with corticosteroid injection. *Foot and Ankle International* 1994;15(7):376–81.
- Shacklock MO. Clinical application of neurodynamics. In: Shacklock MO, editor. *Moving in on pain*. Chatswood: Butterworth-Heinemann; 1995. p. 123–31.
- Shacklock MO. *Clinical neurodynamics: a new system of musculoskeletal treatment*. Edinburgh, New York: Elsevier Butterworth-Heinemann; 2005.
- Shandles ID, Pruchniewski J, Reynolds KL. Heel neuroma: the enigma of recalcitrant heel pain and innovative approach highlighting sixty surgical cases and a review of two hundred and fifty-seven symptomatic but non-surgical cases. *The Foot* 2002;12:10–20.
- Shy ME, Frohman EM, So YT, Arezzo JC, Cornblath DR, Giuliani MJ, et al. Quantitative sensory testing: report of the Therapeutics and Technology Assessment Subcommittee of the American Academy of Neurology. *Neurology* 2003;60(6):898–904.
- Siao P, Cros DP. Quantitative sensory testing. *Physical Medicine and Rehabilitation Clinics of North America* 2003;14(2):261–86.
- Spiegel PV, Johnson KA. Heel pain syndrome: which treatments to choose? *Journal of Musculoskeletal Medicine* 1984;1(11):66–71.
- Tassler PL, Dellon AL. Pressure perception in the normal lower extremity and in the tarsal tunnel syndrome. *Muscle and Nerve* 1996;19(3):285–9.
- Trepman E, Kadel NJ, Chisholm K, Razzano L. Effect of foot and ankle position on tarsal tunnel compartment pressure. *Foot and Ankle International* 1999;20(11):721–6.
- Watson TS, Anderson RB, Davis WH, Kiezbak GM. Distal tarsal tunnel release with partial plantar fasciotomy for chronic heel pain: an outcome analysis. *Foot and Ankle International* 2002;23(6):530–7.
- Wearing SC, Smeathers JE, Urry SR, Hennig EM, Hills AP. The pathomechanics of plantar fasciitis. *Sports Medicine* 2006;36(7):585–611.
- Willis JD, Carter PM. Tibial nerve entrapment and heel pain caused by a baker’s cyst. *Journal of the American Podiatric Medical Association* 1998;88(6):310–1.
- Wong SM, Griffith JF, Hui AC, Tang A, Wong KS. Discriminatory sonographic criteria for the diagnosis of carpal tunnel syndrome. *Arthritis and Rheumatism* 2002;46(7):1914–21.
- Yesildag A, Kutluhan S, Sengul N, Koyuncuoglu HR, Oyar O, Guler K, et al. The role of ultrasonographic measurements of the median nerve in the diagnosis of carpal tunnel syndrome. *Clinical Radiology* 2004;59(10):910–5.